ANATOMIA DAS AVES

Técnica de Necrópsia

Funchal 15 de Março de 2010

Rui Sereno Melo

Cabeça do fémur

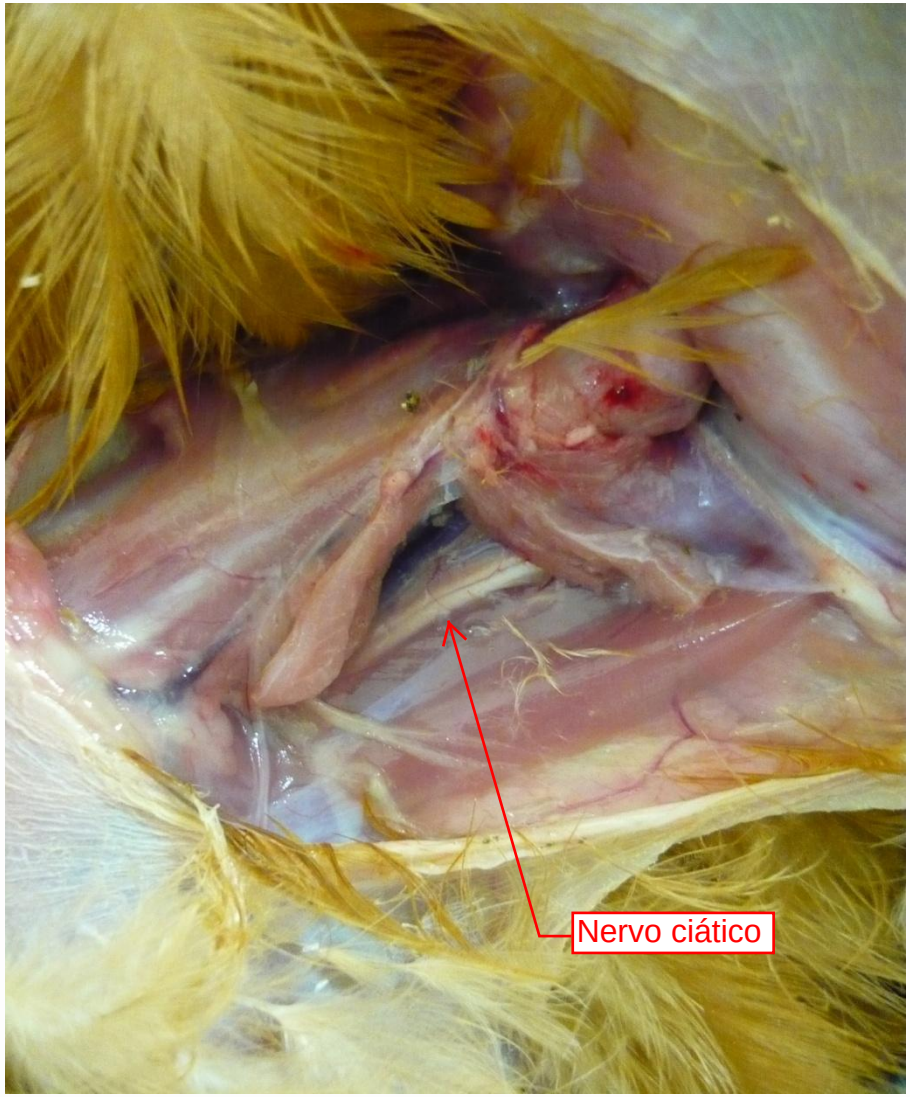
Nervo ciático

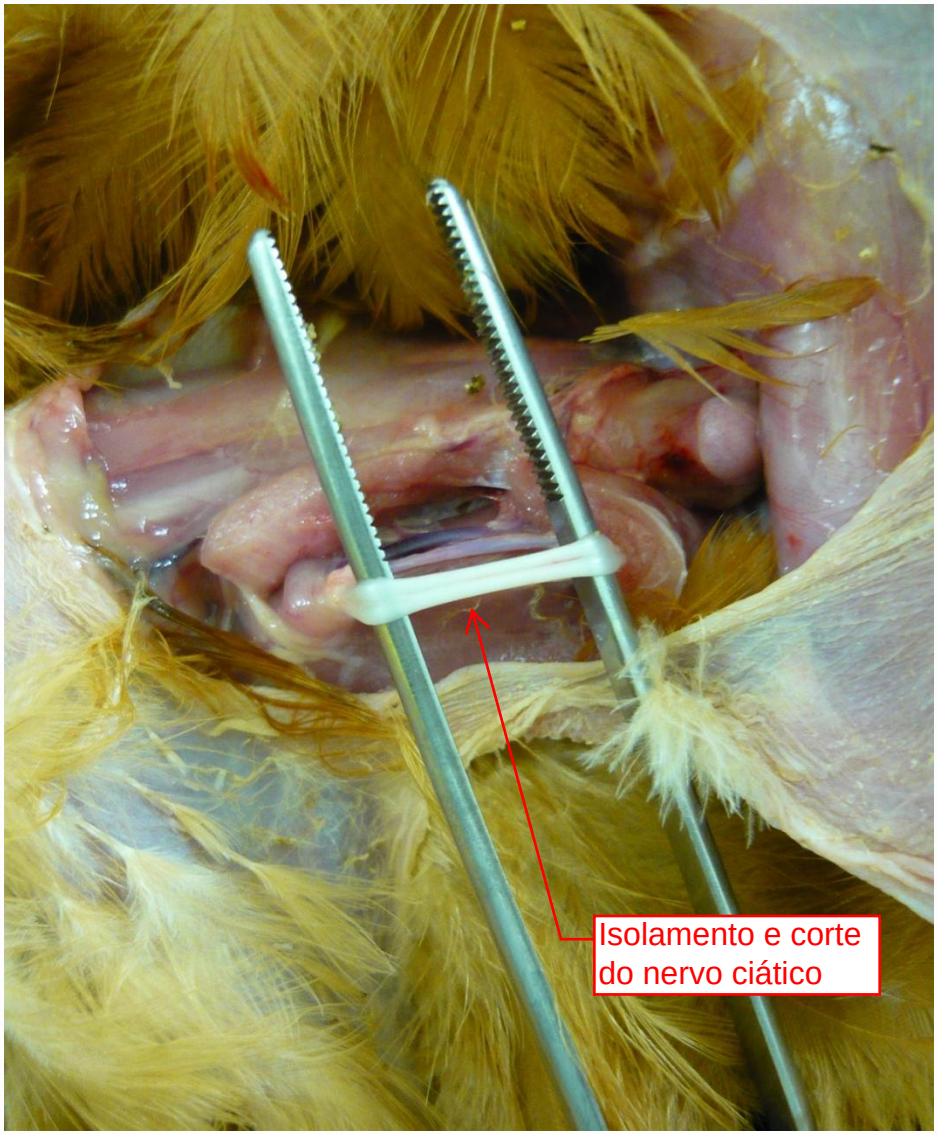
Isolamento e corte
do nervo ciático

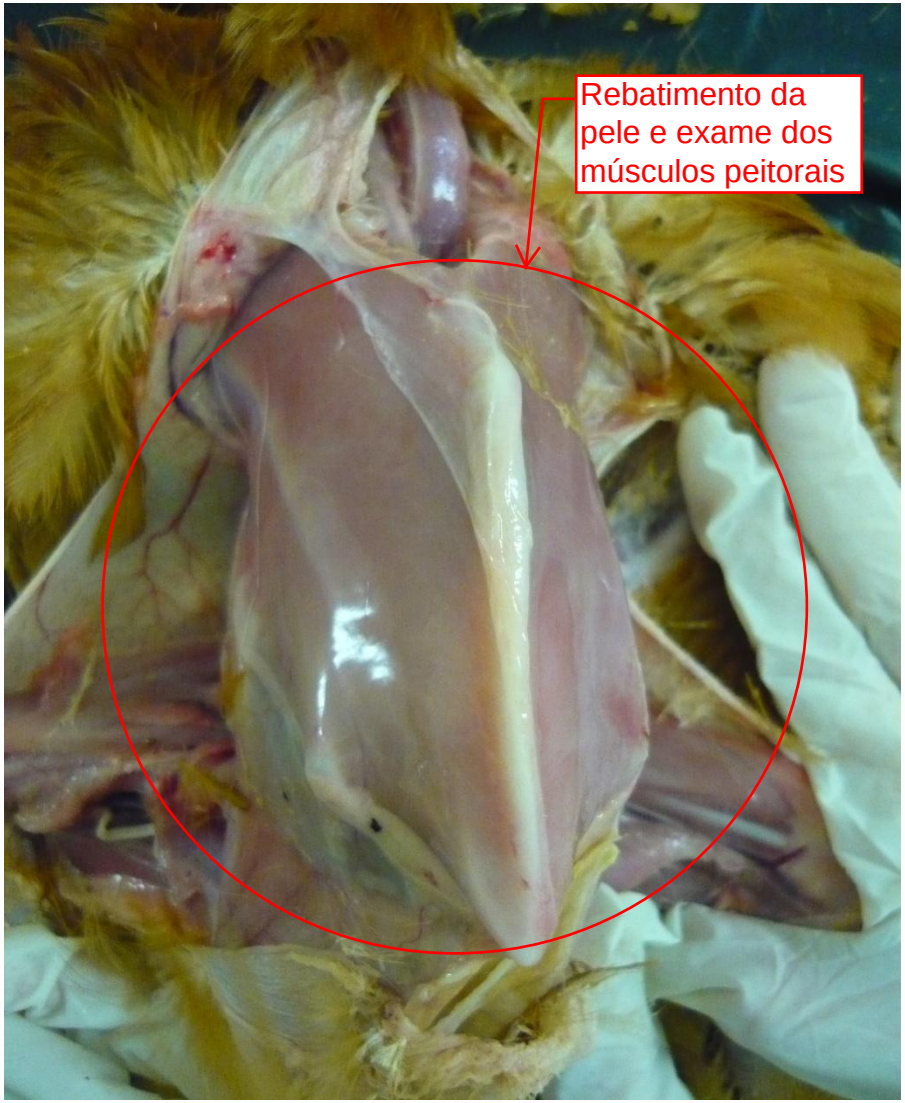
Rebatimento da pele e exame dos músculos peitorais

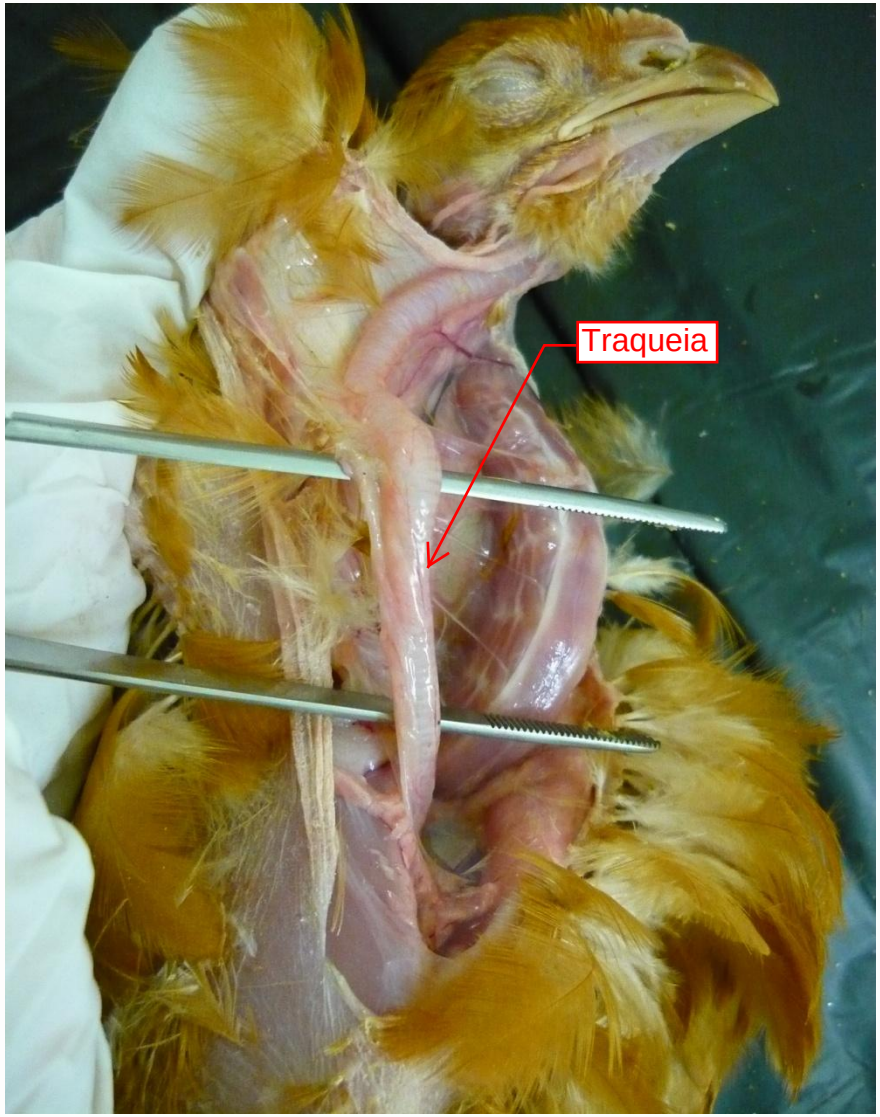
Traqueia

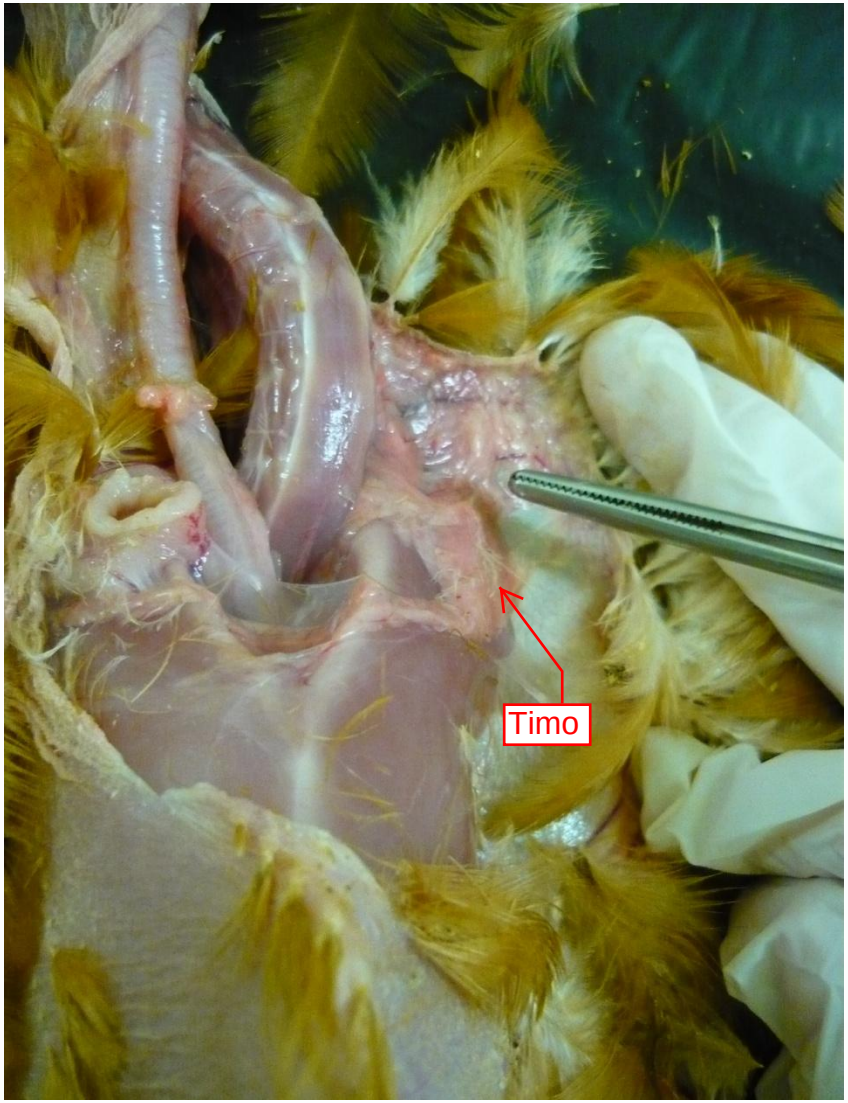
Timo

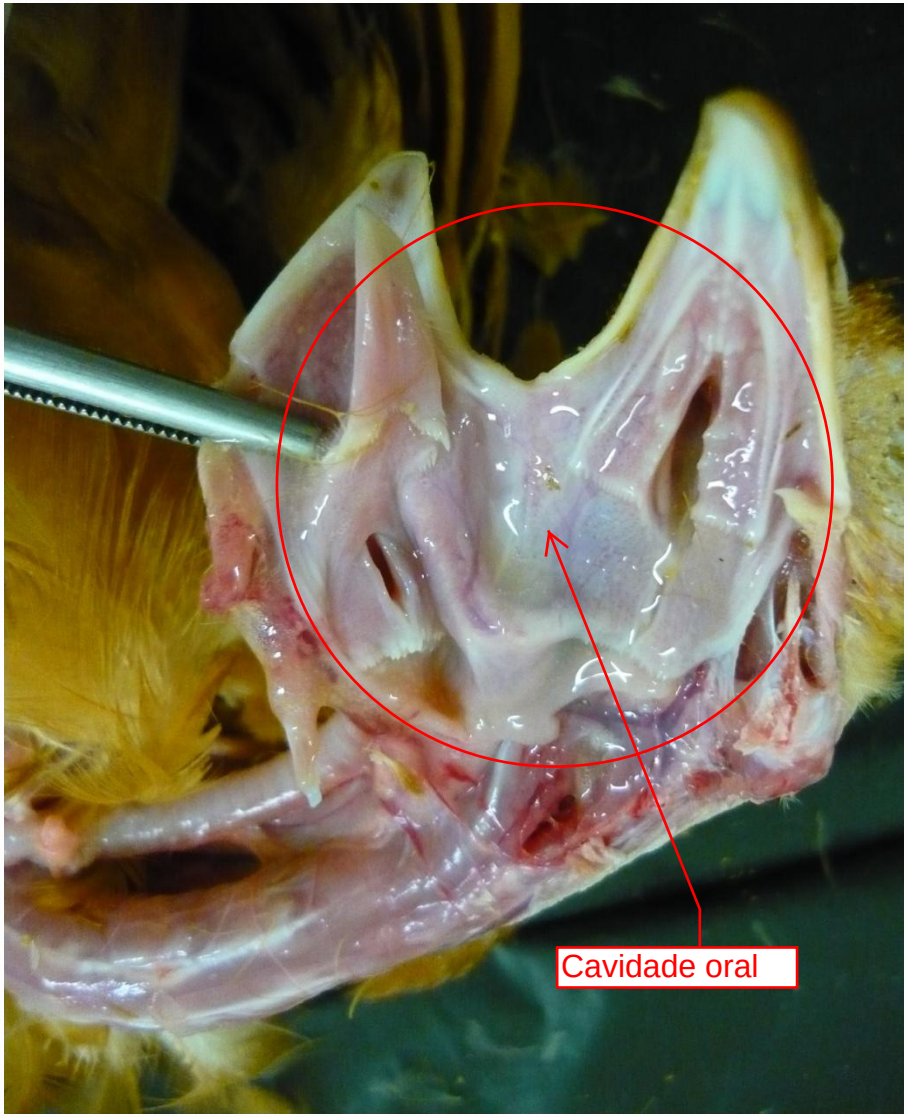
Cavidade oral

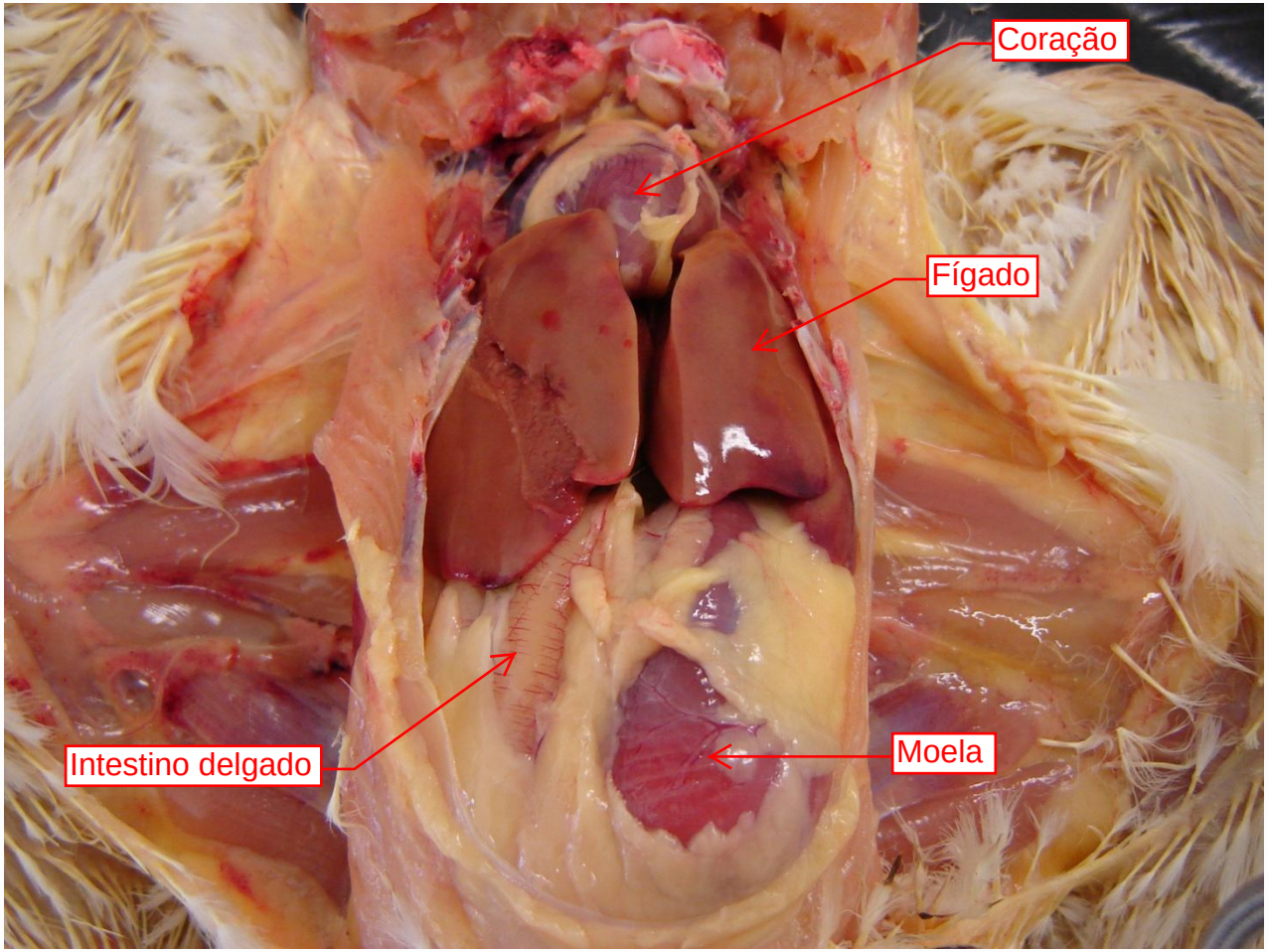
Coração
Fígado
Intestino delgado
Moela

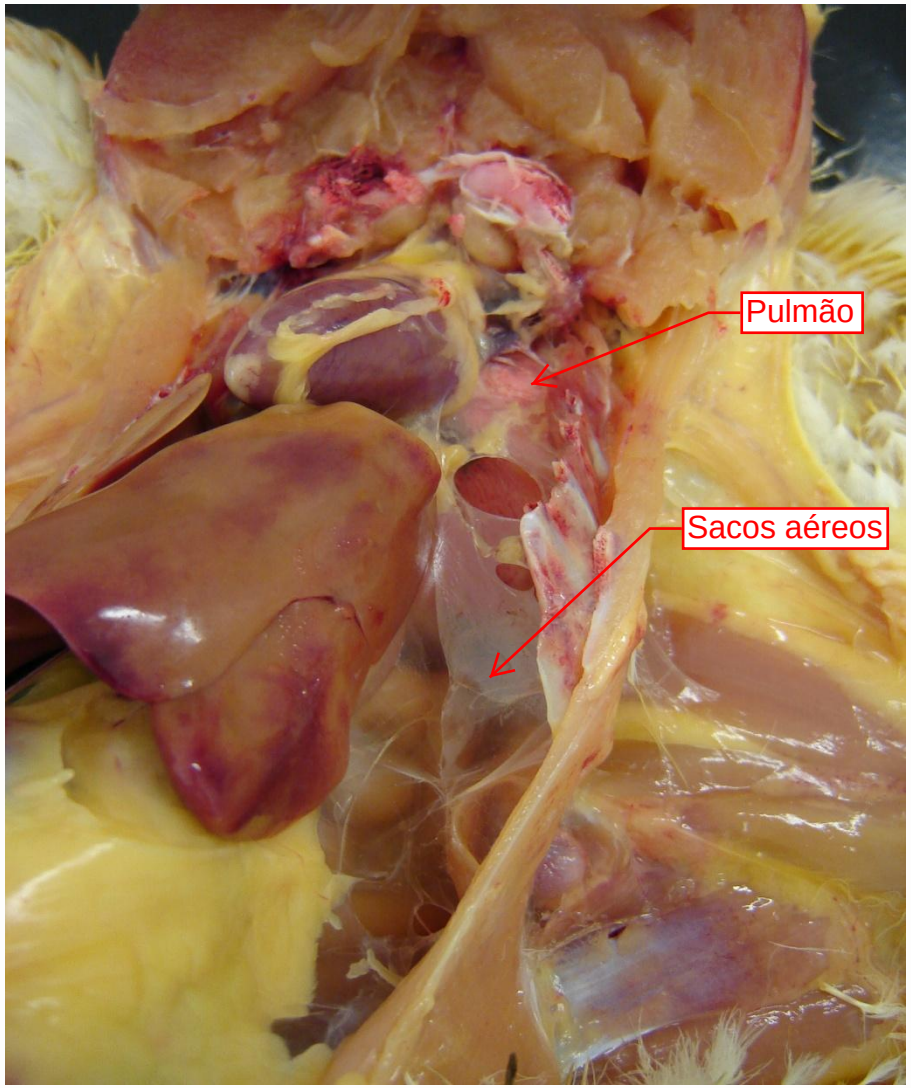
Pulmão
Sacos aéreos

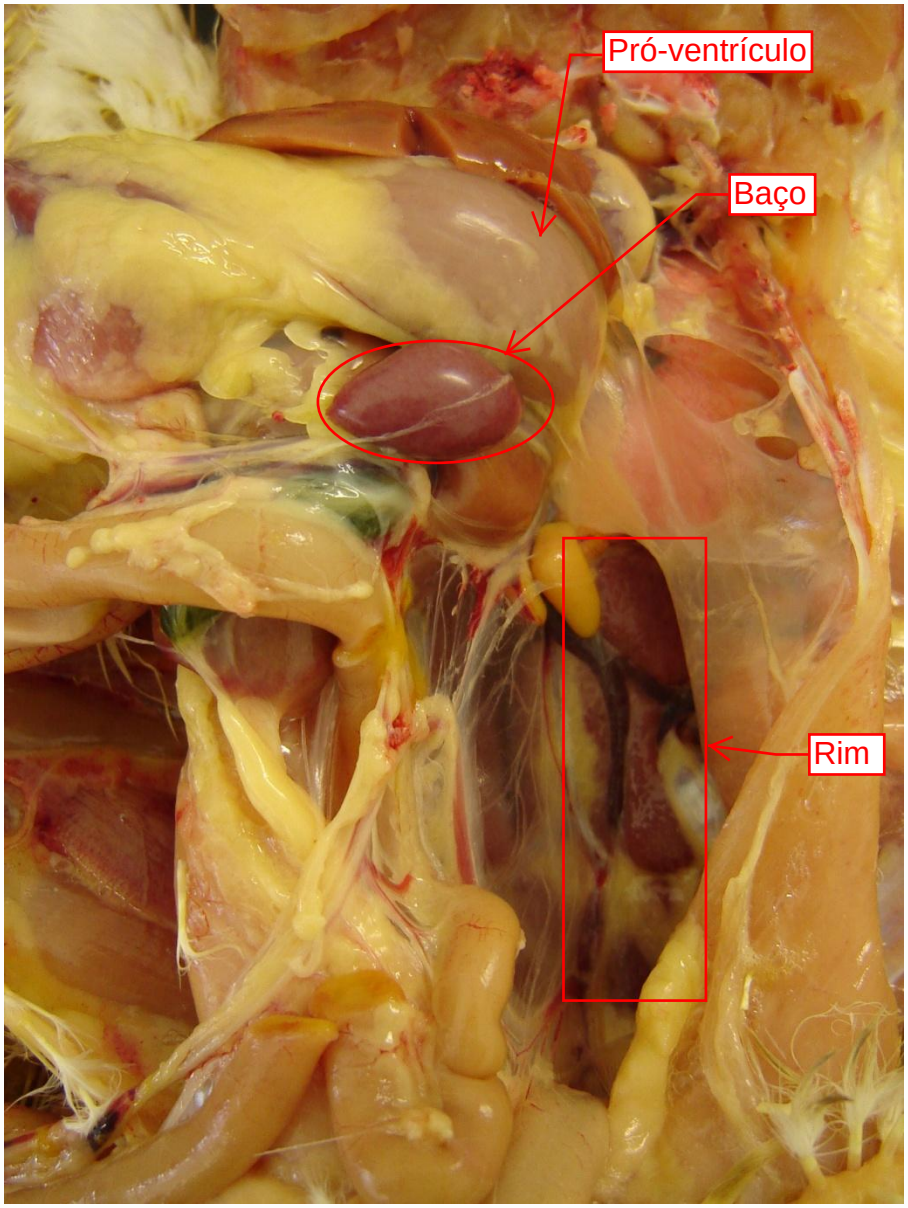
Pró-ventrículo
Baço
Rim

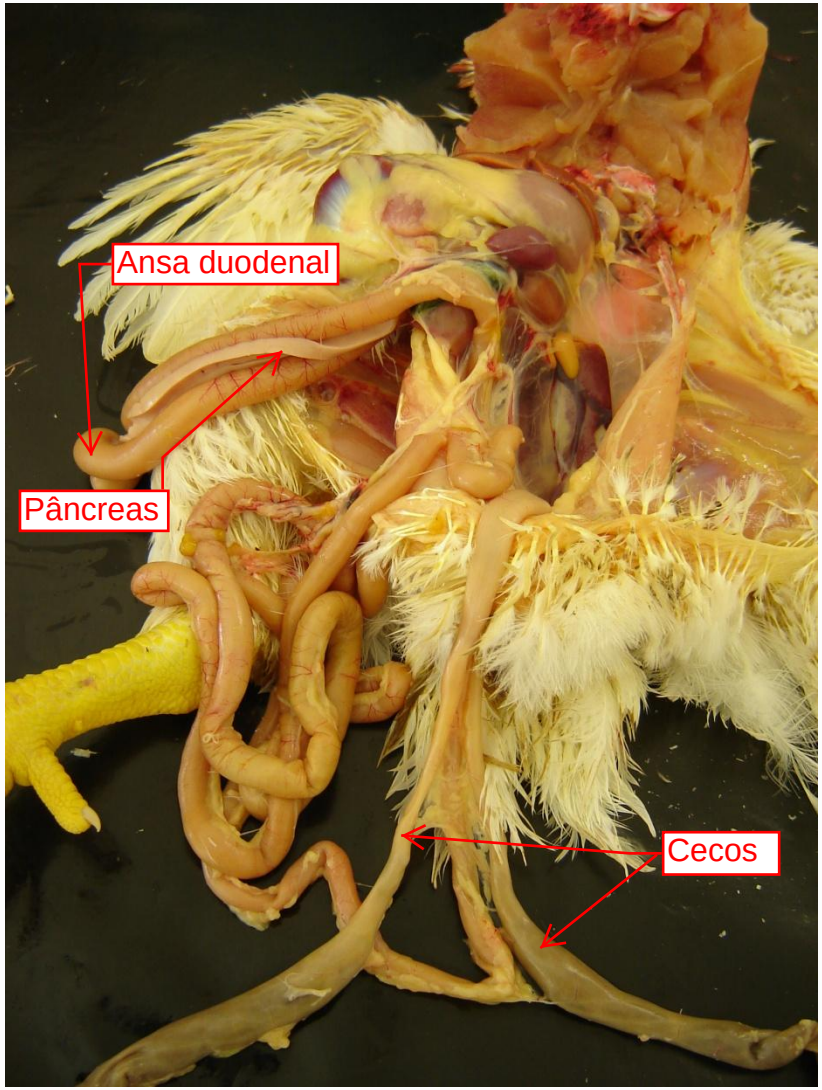
Ansa duodenal
Pâncreas
Cecos

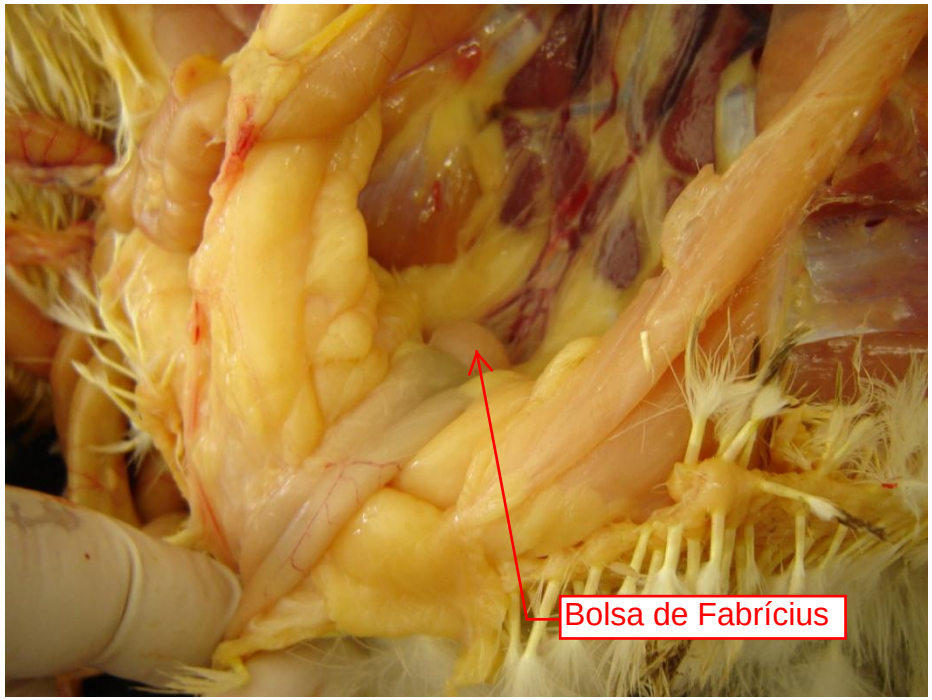
Bolsa de Fabrícius

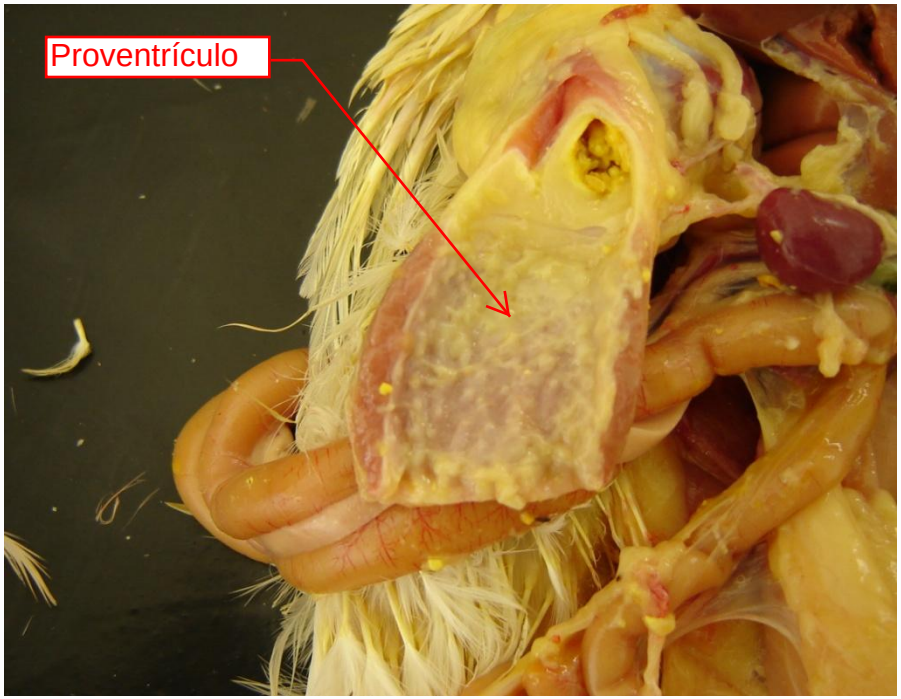
Proventrículo